

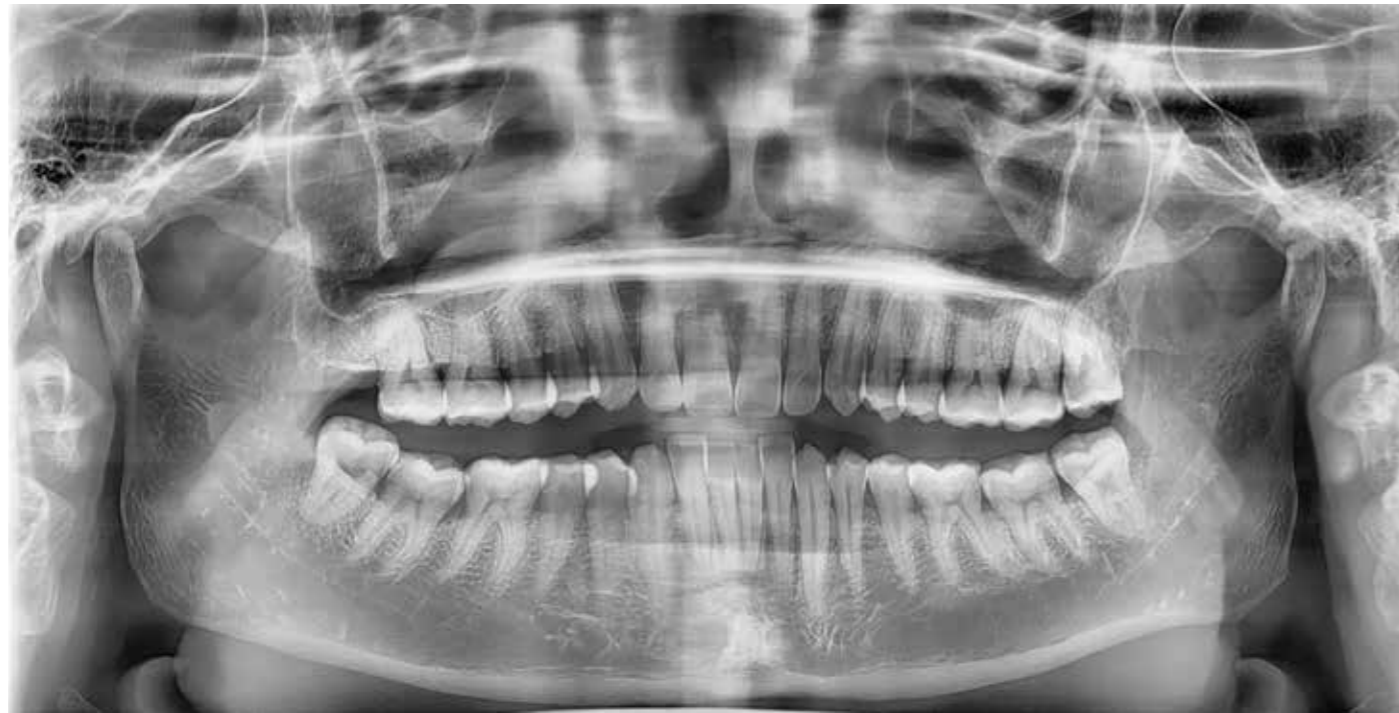

CASE REPORT

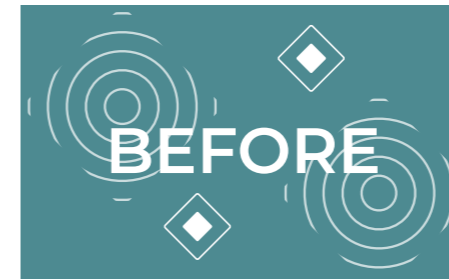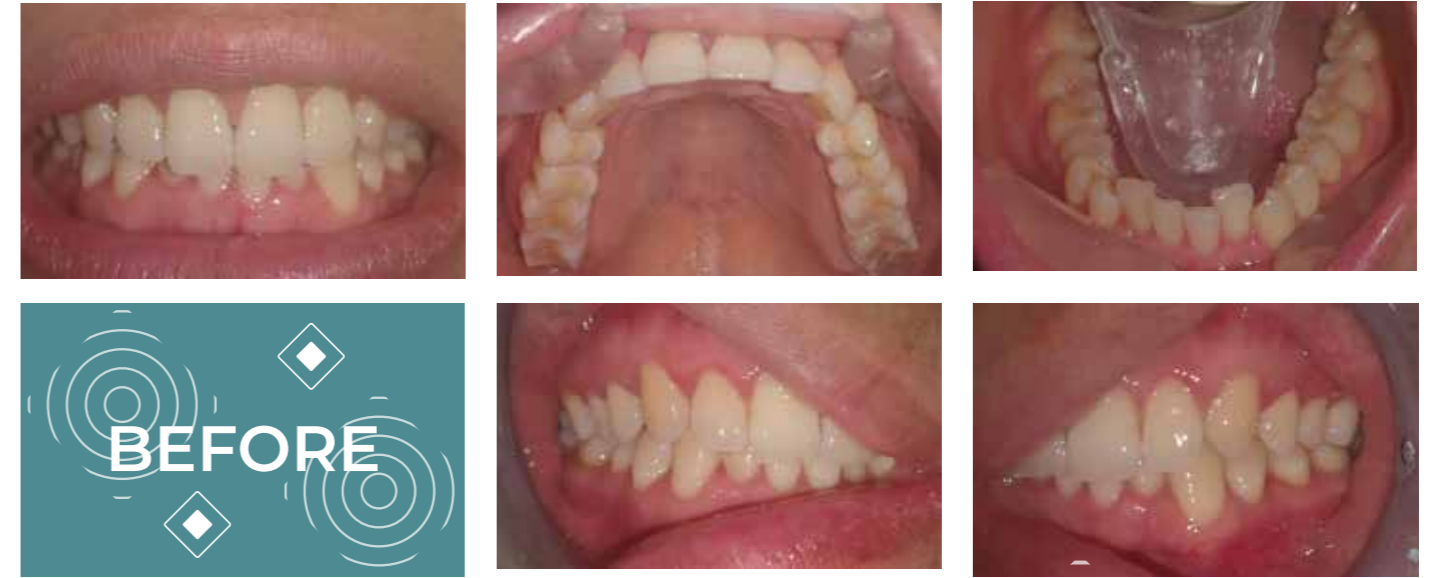
TRIO[®]
CLEAR

INTRODUCTION

This patient consulted me with the request to improve the crowding in the lower jaw. After assessment we noticed small rotations of the 12 and 22 and a deep bite. We approved the treatment plan with 9 cycles and IPR in step 1 and 7. The patient was happy with the end result



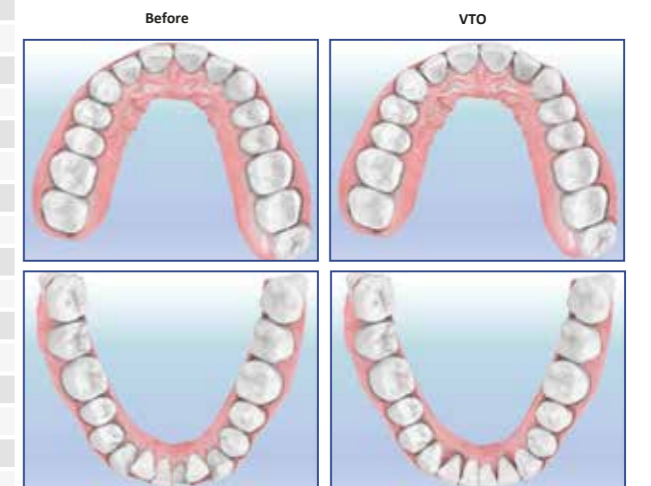
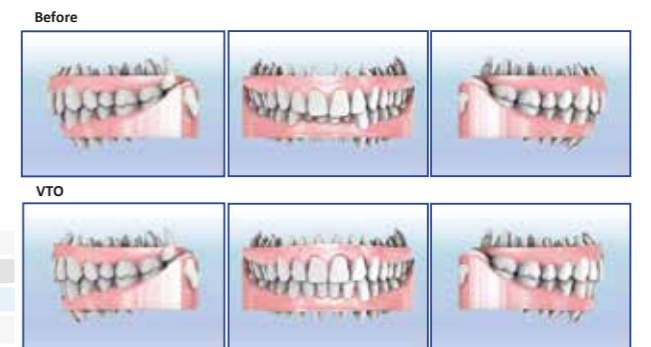TREATMENT STARTING



TREATMENT PLAN

Clear Aligner Treatment Plan 1

19-01-2021



Tx. Time	Maxilla		9 Cycles		
	Mandible		Maxilla	Mandible	
Cycle	Maxilla	Mandible	Cycle	Maxilla	Mandible
1	IPR	IPR	21		
2			22		
3			23		
4			24		
5			25		
6			26		
7	IPR	IPR	27		
8			28		
9			29		
10			30		
11			31		
12			32		
13			33		
14			34		
15			35		
16			36		
17			37		
18			38		

AGE PATIENT 36

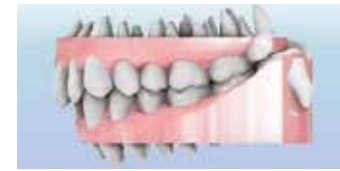ROTATIONS
12 AND 22

SEVERE MANDIBULAR
CROWDING

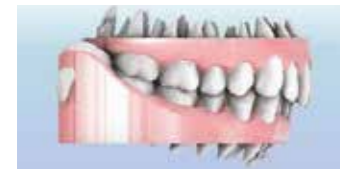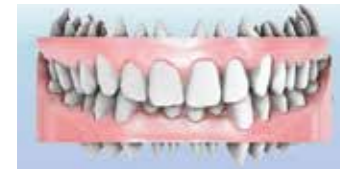PALATAL BITE AT
LEVEL OF 32

SUPRA-OCCLUSION

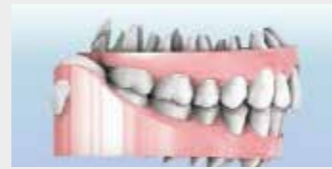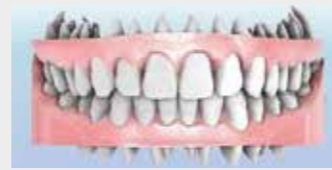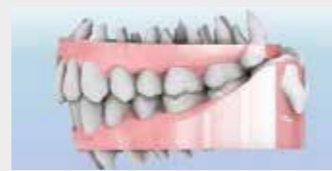BEFORE AND AFTER



BEFORE



AFTER



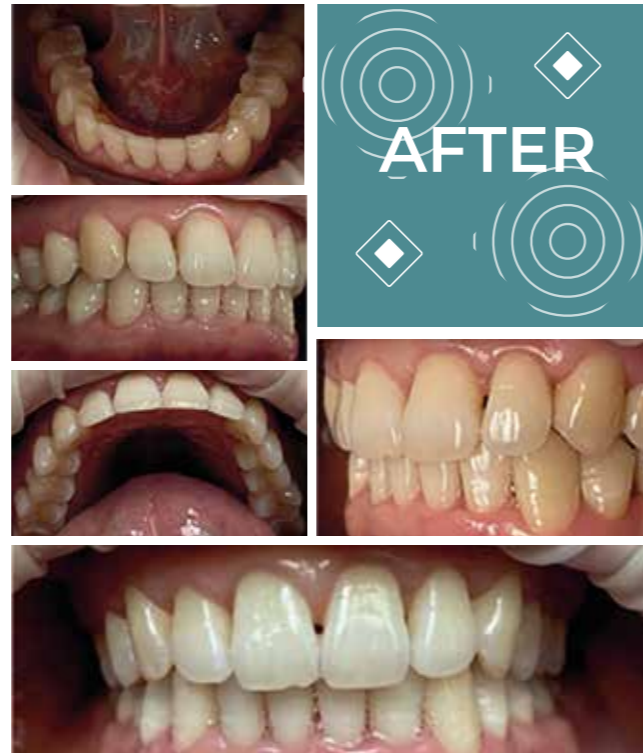CONCLUSION

IMPROVEMENT OF SEVERE CROWDING

IMPROVING DEEP BITE

RESOLVED PALATAL BITE

A DOUBLE RETENTION (REMOVABLE RETAINER AND FIXED RETAINER) AND A FUNCTION CONTROL ARE NECESSARY TO GUARANTEE THE SUSTAINABILITY OF THE END RESULT OF THE TREATMENT



DENTIST AND PATIENT FEEDBACK

Dentist:

"I was satisfied with the outcome of this treatment. The treatment time remained quite limited at the request of the patient and we saw that with this final result her wishes were fulfilled.

We finished this with a 3-cycle refinement afterwards to close the residual spaces. The communication with the designers was easy and everything was well organized. This is the kind of treatments that gives both the doctor and the patient a great satisfaction."

Patient:

"I am very happy to have chosen for this kind of treatment. I could go on with my job presentations without anyone noticing I was in a treatment.

The result is just what I hoped for."





Southern Cross Dental

A Modern Dental Europe Company